

29

Tarsorrhaphy and lacrimal occlusion

Alon Kahana, Mark J. Lucarelli

Corneal desiccation can be vision and eye threatening. The etiology may be inadequate hydration, inadequate coverage, or both. Inadequate hydration is often referred to as 'dry eyes' and its symptoms often, but not always, manifest as foreign body sensation, ocular irritation, and decreased vision. Since other ocular diseases share these symptoms, a careful ocular examination is essential for proper diagnosis and treatment. For example, blepharitis, keratoconjunctivitis, pterygia, and ocular foreign bodies comprise a portion of the differential diagnosis for 'dry eyes'. Valuable portions of the examination include fluorescein and/or rose bengal staining, Schirmer basal tear production test, tear breakup time, and tear meniscus height, as these tests can be extremely helpful for diagnosis and follow-up assessments.

Corneal desiccation can also result from inadequate coverage by the eyelids, leading to corneal exposure and accelerated evaporation of the protective tear film. Inadequate coverage can result from eyelid malposition (e.g. ectropion or entropion), as well as lagophthalmos or poor blink. Hence, inadequate coverage may be related to cicatricial eyelid changes and facial nerve injury, as well as to central nervous system injuries and postoperative changes.

The medical treatment of corneal desiccation includes artificial tears as well as lubricating gels and ointments. For certain etiologies and patients, topical cyclosporin 0.05% (Restasis, Allergan, Inc.) may be helpful. It is important to keep in mind that the goals of therapy are to not only improve discomfort and blurred vision but also prevent ocular surface infections, scarring, and permanent loss of vision.

The neurotrophic cornea can present a particular challenge because lack of corneal sensation can also interfere with the tear secretion pathway, as well as diminish the protective blink reflexes. Hence, an aggressive and comprehensive treatment approach is often necessary to avoid vision-threatening complications.¹

When medical therapy measures prove to be inadequate, more invasive interventions are often required. These may include temporary measures, such as punctal occlusion or temporary eyelid closure (through a temporary tarsorrhaphy), or permanent measures, such as punctal ablation or permanent transposition tarsorrhaphy. The most useful 'permanent' techniques are often reversible, provid-

ing the treating surgeons with maximum flexibility in the care of their patients.

LACRIMAL OUTFLOW: PUNCTAL AND CANALICULAR OCCLUSION

Corneal hydration and protection can be achieved through increased lubrication or decreased evaporation. Hence, an important therapeutic strategy to corneal desiccation involves occlusion of the lacrimal drainage system in order to decrease tear outflow and provide additional ocular surface hydration. Three general approaches can be used: temporary, reversible, or permanent occlusion of the lacrimal drainage system. Often, the treatment approach follows the same progression: temporary occlusion is tested using absorbable punctal plugs. If symptomatic relief and objective improvement are achieved, reversible long-term occlusion is attempted with a nonabsorbable device. In situations where lacrimal outflow occlusion achieves symptomatic resolution but requires frequent replacement or causes ocular irritation, permanent surgical occlusion using a puncto- or canaliculodestructive procedure may be cautiously considered.²

PUNCTAL AND CANALICULAR PLUGS

Occlusion of lacrimal outflow is a hallmark of treatment for moderate to severe corneal desiccation. Since the first description of punctal plugs by Freeman,³ punctal and canalicular plugs have been shown to be effective in treating moderate to severe dry eye conditions.⁴⁻¹¹ Unfortunately, punctal plug placement has often been treated as even less than the minor procedure that it is.¹² Since lacrimal occlusion may be associated with complications, some of which may be quite significant, educating the patient about the risks, benefits, and alternatives to treatment would be appropriate.¹³⁻²³ Informed consent should be obtained prior to undertaking the occlusive measures. A careful ophthalmic examination with quantifiable measures (e.g. Schirmer test, corneal staining, tear lake height, fluorescein dye disappearance test, etc.) will facilitate determination of efficacy in follow-up visits.

A perfect occluder of the lacrimal drainage system would be easy to fit, simple to insert, and nonirritating, provide complete occlusion, last as long as needed, and be straightforward to remove. Alas, such a plug has not yet been devised. However, the modern clinician currently has a multitude of options from which to choose, each with its own advantages and disadvantages.

Temporary punctal plugs are made of a variety of absorbable materials, such as collagen, hydroxypropyl cellulose, gelatin, and catgut, and, after placement in the punctum, can last for approximately a week. These plugs are often used to test the efficacy and tolerability of punctal occlusion in the treatment of the patient's symptoms. A more durable but absorbable punctal occlusion can be achieved with plugs made of synthetic absorbable material (polycaprolactone or PCL), which can last 2–6 months (e.g. DuraPlug, Eagle Vision).

GRADED PUNCTOCANALICULAR OCCLUSION

On many occasions, a stepwise lacrimal occlusion is undertaken, and occlusion of only one canaliculus may produce sufficient relief. One functional punctocanalicular system appears to be sufficient for draining basal tearing but may not be sufficient for draining reflex tearing.^{24,25} Many ophthalmologists, when choosing to occlude only one punctocanalicular system, preferentially choose to occlude the inferior one because of its accessibility.⁷ However, several experimental studies suggest that the upper and lower canaliculi drain fairly equivalent volumes of tears.^{25–29}

The choice of which punctum to occlude should take into account the ease of performing the occlusion procedure and the relative risk of failure. With punctal plugs, one common cause of failure is plug extrusion. Several studies have shown that an upper punctal plug is more likely to extrude than a lower punctal plug.^{4,6} This may be related to the challenge of properly fitting the superior punctum or to an increase in ocular irritation associated with a punctal plug that moves across the ocular surface thousands of times per day. Another possible explanation is simply that the upper lid punctum moves much more than the lower lid punctum.

It has also been argued that after plug extrusion, a second plug may be even more likely to extrude.^{4,6} One possible explanation is that by evaluating patients who have already experienced punctal extrusions, the authors may have selected for puncta that are larger, more flexible, and harder to fit. These individuals may also experience plug-related discomfort, leading to eyelid rubbing, which can result in recurrent plug extrusion. Another possibility is that over-dilation of the punctum at the time of plug insertion caused trauma to the punctal annulus, which would result in a poor punctal plug fit on subsequent insertions.

The need for long-term but reversible punctal or canalicular occlusion led to the development of a variety of nonabsorbable plugs that fit snugly into the ampula or canaliculus. These fall into two general categories: punctal plugs and intracanalicular plugs. Punctal plugs are made of synthetic materials (e.g. silicone or polyethylene) and fit on the punctum (Fig. 29.1). The advantages of the punctal plug are simple placement, easy monitoring, and usually straightforward reversibility. The disadvantages include a high extrusion rate and occasional ocular irritation and epiphora.^{4,6} Extrusion often results from a poorly fitting plug, although patients can also dislodge a well-fitting plug by rubbing.


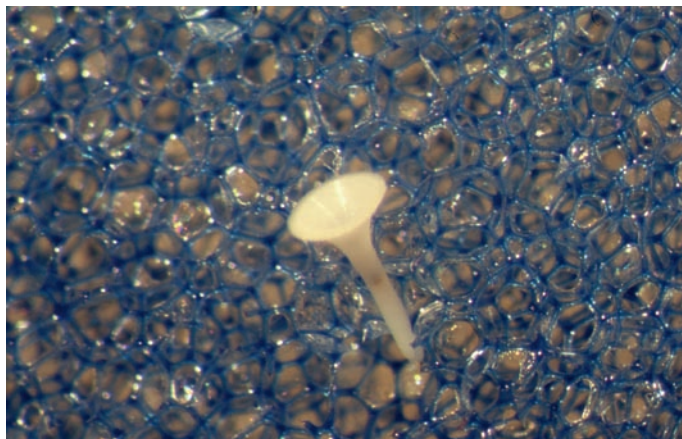


Figure 29.1. The Freeman-style silicone punctal plug (photo courtesy of Ayad A. Farjo, MD).

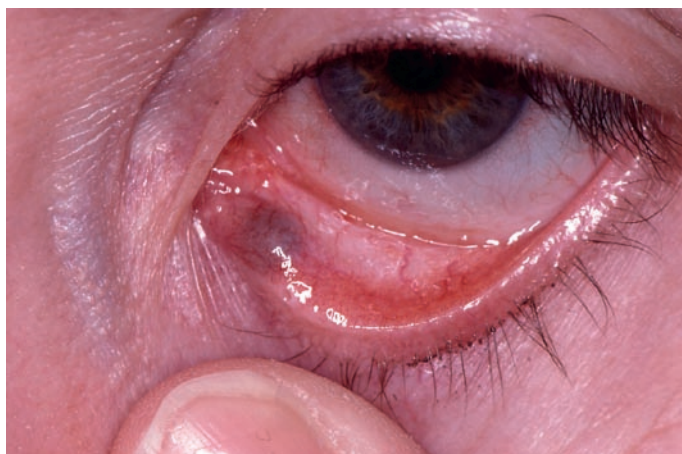
INTRACANALICULAR OCCLUSION

The use of intracanalicular plugs is controversial. The Herrick plug (Lacrimedics, Inc.) is made of silicone and is designed for permanent placement inside the horizontal section of the canaliculus (Fig. 29.2, A). It is simple to place and can provide effective lacrimal occlusion,⁵ but can be difficult to monitor and can cause complications such as granuloma formation, infection, scarring, and nasolacrimal duct obstruction with dacryocystitis^{13,30,31} (Fig. 29.2, B). In theory, the Herrick plug was designed to be easily irrigated out of the canaliculus. However, several published studies have noted the unpredictability of Herrick plug removal. A recently introduced modified Herrick plug, the opaque Herrick plug (Lacrimedics, Inc.), may make it easier to monitor plug placement but does not address the other issues associated with the original Herrick intracanalicular plug. A dissolvable version of the opaque Herrick plug, made of polydioxanone, is now available and is designed to last approximately 6 months. At the time of writing, no comparative studies have been published regarding long-term efficacy and safety. It is interesting to note that an article was published by Dr Herrick describing his preferred techniques for canalicular reconstruction after canalicular scarring related to a Herrick plug.³²

The SmartPlug (Medennium, Inc.) is a thermosensitive acrylic plug that changes its shape at body temperature to fit into and completely occlude the ampula and canaliculus. Specifically, it expands when warm and contracts when cold. The SmartPlug is simple to insert, but also difficult to monitor. It was designed to be a 'one-size-fits-all' plug that would not need to be fitted and would be easier to remove by irrigating the canaliculus with cold water. It can be useful in patients for whom Freeman-style punctal plugs are not a good option.⁸ However, over the short time period of SmartPlug availability, a similar series of untoward side effects that have been reported with the Herrick plug are beginning to be reported to occur with the SmartPlug. As with the Herrick plug, the location of the SmartPlug can be more difficult to confirm (especially when the canaliculus is only partially occluded), and the plug



A



B

Figure 29.2. Intracanalicular plugs. *A*, The Herrick-style intracanalicular plug. *B*, Canalicular damage requiring surgical intervention. The plug in *A* was retrieved.

can either migrate when it should not or fail to get flushed out of the canaliculus when a reversal of the procedure is desired.^{14,33} When the need for reversal arises, failure may lead to infections, surgery for canalicular reconstruction, and dacryocystorhinostomy (DCR).¹⁴ Nevertheless, the SmartPlug may be the only good option in patients with stenotic puncta (under 0.3 mm) who require lacrimal outflow occlusion.

Given the difficulty of monitoring lacrimal occlusion with an intracanalicular plug, along with the somewhat higher rate of complications with such plugs, our bias is for using well-fitting Freeman-style silicone punctal plugs such as the Eagle plugs (Eagle Vision, Memphis, TN). While these plugs are not complication free, they are simple to fit and insert, easy to remove, and straightforward to monitor, and rarely migrate deep into the canaliculus. The exceptions are patients who report significant ocular irritation with Freeman-type plugs or patients whose stenotic puncta are too small for any commercially available punctal plugs. For these patients, other measures should be considered.

PUNCTAL PLUG INSERTION

Insertion of a synthetic plug into the ampula is done at the slit lamp (Fig. 29.3). First, the ocular surface is anesthetized with a topical

anesthetic such as proparacaine. It is often useful to also treat the punctum directly with a topical anesthetic by applying proparacaine to a cotton-tipped swab, placing it between the upper and lower puncta next to the caruncle, and asking patients to close their eyes for 1–2 min. This can achieve excellent short-term anesthesia and comfort.³⁴ Next, the correct plug size is chosen using a punctal gauging instrument. The end point should be a snug fit that requires some gentle pressure for insertion and removal, causing slight expansion of the punctal tissues. When a perfect fit cannot be obtained, a slightly larger plug may be preferable to one that is too small.^{4,6,21} Care must be taken not to overly stretch the punctal annulus, since such trauma may dramatically increase the risk of punctal migration or extrusion. The punctum should then be dilated very slightly using a punctal dilator. Dilation allows the correct size plug to be inserted, with the punctal tissues closing around the plug to form a good seal. We favor a reusable and autoclavable stainless steel dilator (such as the Wilder or the Hosford from Storz, Inc.) over the relatively blunt, plastic disposable dilator often provided with Freeman-type plugs. The plug is then inserted with the provided applicator or a generic applicator.

The end point should be a fit that is flush with the lid margin surface (Fig. 29.3, C). If the plug is too small, it could easily migrate and lodge in the ampula or fall out of the punctum, whereas if the plug is too large, it will distort the punctal anatomy and cause discomfort and possible annulus damage and punctal stretching. Removal is usually easy, using toothed or non-toothed forceps to grasp the flange of the plug and remove it.

The disadvantages of Freeman-style plugs include a high extrusion rate and occasional ocular irritation. Extrusion often results from a poorly fitting plug, although patients can also dislodge a well-fitting plug by rubbing. Techniques have been published for suture anchoring of punctal plugs,³⁵ but with a good fit and control of rubbing, punctal plugs should remain effective for a significant duration without additional surgical steps.

PERMANENT PUNCTAL/ CANALICULAR OCCLUSION

A variety of surgical techniques have been devised for permanently blocking tear drainage through the lacrimal drainage system. These include punctal ablation with cautery or Argon laser,^{36,37} canalicular ligature,³⁸ canalicular excision,³⁹ punctal tarsorrhaphy, and punctal patch (for a review, see ref. 2). All the techniques share as a basic principle the introduction into the lacrimal drainage apparatus of a discontinuity that would block outflow. The most common techniques are punctal ablation with thermal cautery, electrocautery (diathermy), or argon laser. In recalcitrant cases, where punctal continuity is re-established, a combination of punctal ablation and canalicular ligature may offer the simplest and most efficacious outcome (Charleux 1978, as described in ref. 2).

Punctal ablation can be most easily performed with a battery-operated thermal cautery unit according to previously published methods.⁴⁰ A local anesthetic should first be injected so that discomfort will not limit the appropriate treatment needed for punctal ablation. Pressure anesthesia may also be effective.³⁴ The ocular surface is anesthetized with proparacaine and a lubricated corneal protective shield may be placed. The looped tip should be inserted deep into the punctum to the full depth of the ampula and vertical canaliculus before the cautery unit is activated (Fig. 29.4). The tip should be rocked and rotated inside the punctum so that the entire circumference of the punctum and vertical canaliculus are treated.

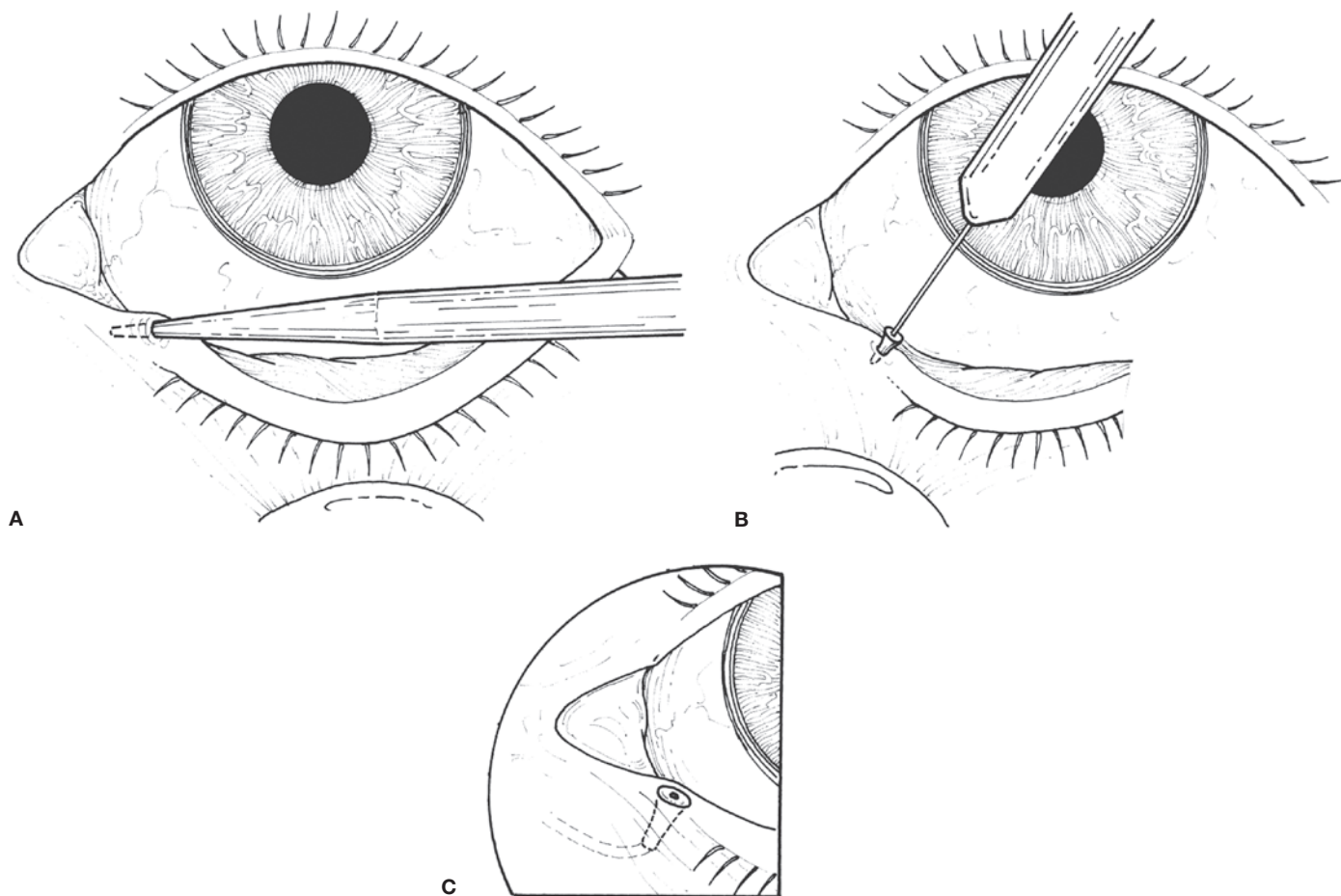


Figure 29.3. Punctal plug insertion. After punctal sizing, the punctum is gently dilated (A), and the plug is inserted (B). Following insertion, the plug should be flush with the lid margin (C).

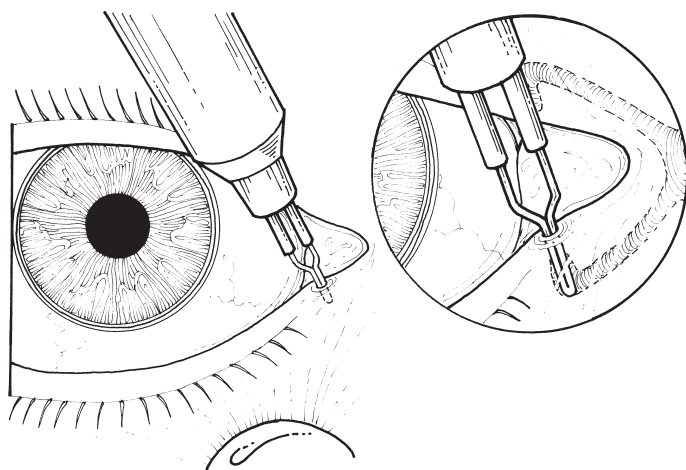


Figure 29.4. Thermal cautery of the punctum. The cold tip is placed deep into the punctum. After activation, blanching of the surrounding tissues indicates sufficient treatment. The tip should be turned around in the punctum and removed while still hot.

The tip should be removed while still hot so that adherent epithelium will be removed. Permanent adhesion and scarring require the removal of the epithelium; otherwise, the canalicular mucosa can heal and recannulate the punctum. Tissue swelling is typically sufficient to oppose the raw surfaces to create scarring and punctal closure. On occasion, placement of a simple interrupted absorbable

suture through the cauterized punctum helps to achieve the required apposition.

Care should be taken throughout the procedure to avoid injury to the globe and adjacent tissues, especially during insertion, removal, and movement of the hot tip (a protective shield is particularly helpful in this regard). Punctal ablation with electrocautery can employ a partially insulated tip that will properly treat the deep vertical canaliculus and ampulla while leaving the punctal opening intact.² Argon laser-assisted punctal ablation techniques vary, but a general guideline is to use 100–200 μm spots and start at 200 mW over 0.1–1.0 s. When the patient is lightly pigmented, dyeing the punctal epithelium with a marking pen⁴¹ or a drop of blood from the anesthetic injection site⁴² will facilitate absorption of the laser power. The power should then be titrated to effect, typically to significantly higher power settings. Initial spots should surround the punctum to contract and delineate it. Further surrounding of the punctum with laser burns will leave the punctal tissues elevated and isolated. Finally, laser burns should be applied directly to the punctum. Charring must be removed with forceps or cotton-tipped swabs before continuing. Sufficient laser burns should be applied to cause contracture and closure of the punctum. Variations on this technique have been described.²

Finally, canalicular excision and punctal ligation are two surgical techniques that obtain punctocanicular destruction under direct visualization. Methods for each have been described,^{38,39} but the underlying principle remains the introduction of permanent and complete scarring into the lacrimal drainage system.

TARSORRHAPHY

Tarsorrhaphy, or surgical closure of the eyelids, is an extremely powerful surgical tool for the protection of the cornea and ocular surface.⁴³ It has very few contraindications and can generally be reversed. Suture tarsorrhaphies can be performed at the bedside with local anesthesia under most circumstances. The indications include paralytic lagophthalmos from facial cranial nerve (VII) damage,⁴⁴⁻⁴⁶ cicatricial lagophthalmos,⁴⁷⁻⁵¹ postsurgical lagophthalmos and exposure,^{52,53} poor blink reflexes and incomplete blink, dry eyes (including keratoconjunctivitis sicca and filamentary keratitis), neurotrophic and congenital neurogenic keratopathies,⁵⁴⁻⁵⁶ and non-healing sterile keratopathies with thinning.^{57,58} Lateral tarsorrhaphies have even been employed for the treatment of floppy eyelid syndrome.⁵⁹ Tarsorrhaphy can be performed for short-term efficacy, lasting days to several weeks, or as a permanent (but still reversible) protective measure that uses epithelialization and scar formation to maintain lid margin adhesion.

An assessment of the indication for a tarsorrhaphy must include an eye examination, with a careful evaluation of the cornea. The presence of an active ocular infection is generally a contraindication for a complete tarsorrhaphy. In the infrequent instance in which a complete tarsorrhaphy may be necessary, a comprehensive eye examination would be indicated prior to placement of the tarsorrhaphy.

The choice of temporary vs. permanent tarsorrhaphy is not always clear cut. The so-called 'permanent' tarsorrhaphy can still be divided with relative ease, although it would require a local anesthetic and careful technique to avoid untoward sequelae. Conversely, temporary suture tarsorrhaphies can often be effective for as long as 3 months, providing an easily reversible lid closure technique that can be a useful alternative to the more invasive 'permanent' transposition tarsorrhaphy. At the time of surgical planning, the predicted period needed for lid closure must be assessed. When in doubt, a temporary suture tarsorrhaphy can be placed, using an easily reversible technique that would allow for periodic opening of the lids for ocular examination, followed by reclosure of the lids if needed.

To enhance effective duration, 4-0 polypropylene suture is employed, and the lid is divided into medial, central, and lateral thirds, each supported by a dedicated tarsorrhaphy suture and two bolsters (see description below). Some surgeons prefer silk, but in our experience, silk causes more local inflammation and irritation and hence cannot be kept in place as long as nonreactive synthetic sutures such as polypropylene or nylon.

Occasionally, a tarsorrhaphy is required for a child of amblyogenic age. In such children, amblyopia may develop rapidly, and comanagement with an experienced pediatric ophthalmologist is essential.

SIMPLE TEMPORARY SUTURE TARSORRHAPHY TECHNIQUE

The simple suture tarsorrhaphy involves approximation of the eyelids with a permanent suture over a bolster, to protect the eyelid margin tissues. A double-armed 5-0 polypropylene suture is often used, unless the tarsorrhaphy is needed for over 4 weeks, in which case a 4-0 double-armed polypropylene suture is used. The polypropylene suture is very well tolerated and maintains tensile strength, allowing the suture tarsorrhaphy to remain in place for up to several months. Another commonly used suture is 4-0 silk,

although local tissue reaction may limit the tolerated duration and require earlier removal.

Many different materials can be used for bolsters. However, for simplicity, sterility, and availability, the silicone tubing from a butterfly phlebotomy needle kit is a superior choice (such kits are available with differing needle gauges, but the tubing is typically the same). After the tubing is cut into small segments that are 2-3 mm long (Fig. 29.5, A), a needle is threaded through a tubing segment. Both needles are then passed through skin and tarsus and out through the gray line of the lower lid (Fig. 29.5, B), and then through the gray line of the upper lid and then out through skin 3 mm above the lashes (Fig. 29.5, C). Care must be taken to avoid injury to the globe during needle passage. Everting the lid margin with Adson forceps while the needle is passed can be helpful in this regard. One needle is then threaded through a second 3-mm silicone bolster, and the suture is tied tightly (Fig. 29.5, D). Tying the suture over the upper lid may prevent suture-related irritation caused by tissue crowding in the lower lid area. As many as three such sutures can easily be placed to achieve anywhere from a localized lid closure to a complete closure. Additional sutures also allow the tarsorrhaphy to remain effective for significantly more time.

ABSORBABLE TEMPORARY SUTURE TARSORRHAPHY TECHNIQUE

Occasionally, a temporary tarsorrhaphy is indicated where a patient may find it difficult to present for tarsorrhaphy removal.^{60,61} In such a situation, a 4-0 chromic gut suture can be used to approximate the lateral eyelid margins without a bolster. Care must be taken not to overtighten the suture. An ophthalmic ointment is prescribed to help with the timely absorption of the suture. When placing central eyelid tarsorrhaphies, this technique should be avoided, since the suture may irritate the cornea during the absorption process as the eyelid margins separate.

An alternative technique for short-term tarsorrhaphy is the use of cyanoacrylate glue (e.g. Dermabond, Ethicon, Inc.).⁶²⁻⁶⁸ However, the duration of action may be less predictable, and glue may come in contact with the ocular surface, resulting in irritation. Nevertheless, this can be a useful technique in selected cases.

REVERSIBLE KNOT TEMPORARY SUTURE TARSORRHAPHY TECHNIQUE

When a tarsorrhaphy is required along with frequent ocular examinations, as is often the case with corneal thinning, a simple technical variation can be performed.^{69,70} Each bolster can be sutured to the eyelid with partial-thickness tarsal bites, using 5-0 polypropylene or nylon suture. Protective corneal shields may be used when making the partial thickness tarsal passes. A 4-0 nylon, polypropylene, or silk suture can then be threaded through the bolsters, pulled, and tied to approximate the lids. This suture can then be cut in subsequent office visits, the lids separated for a complete ocular examination, and then a new suture threaded through the bolsters for reclosure of the lids.

SURGICAL APPPOSITION AND TRANSPOSITION TARSORRHAPHY TECHNIQUES

The indications for a permanent tarsorrhaphy are varied but have the following in common: chronic exposure keratopathy that cannot be effectively treated with enhancement of lubrication (in

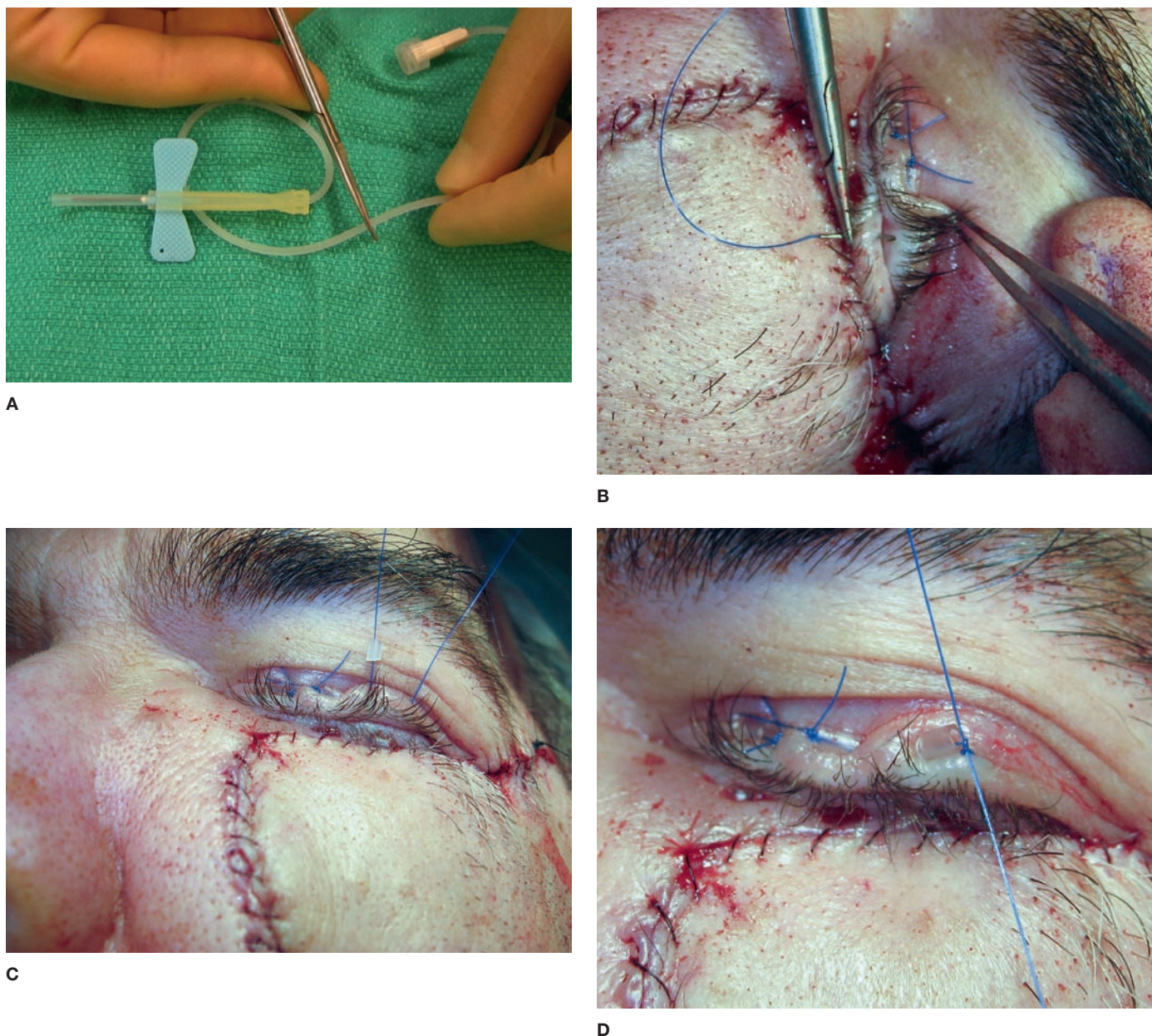


Figure 29.5. The temporary suture tarsorrhaphy using double-armed 4-0 polypropylene suture and tubing from a butterfly needle kit. *A*, The tubing is cut into small segments for bolsters. One needle is threaded through a bolster. *B*, Each needle is then passed in a partial thickness fashion through skin and tarsus, exiting at the gray line. *C*, Needle passage through upper lid margin and threading of the second silicone bolster. *D*, The sutures are tied to provide good lid margin apposition.

the form of lubricating preparation or punctal occlusion) or with the placement of a gold weight for paralytic lagophthalmos. The cosmetic and psychological aspects of a permanent tarsorrhaphy must be addressed preoperatively. At times, placement of a temporary tarsorrhaphy allows the patient to properly evaluate the effectiveness of the procedure before committing to a permanent tarsorrhaphy.

The technique, in its standard form, has been well described in numerous publications. Briefly, the anterior and posterior lamellae are split with a #11 Bard-Parker blade. The segments of the lid margins where adhesion is desired are de-epithelialized to expose raw edges on both the upper and the lower lids. The lash line and lateral commissure are spared. For apposition tarsorrhaphy, the

anterior and posterior lamellae are then sutured using 4-0 chromic gut or 6-0 polyglactac acid (Vicryl) sutures, keeping the knots away from the ocular surface.

The 'tongue-in-groove' transposition technique provides a stronger adhesion but may be more challenging to reverse. Following splitting of the anterior and posterior lamellae and removal of the posterior lamellar epithelium, a short segment of inferior tarsus is removed, and the upper lid tarsus is fashioned for transposition into the newly created tarsal notch (Fig. 29.6). The epithelium of the anterior lamella is left undisturbed. A double-armed 4-0 chromic gut suture or 6-0 polyglactac acid suture can be used to attach the tarsal edges, using partial-thickness tarsal passes to reduce ocular irritation during the healing process.

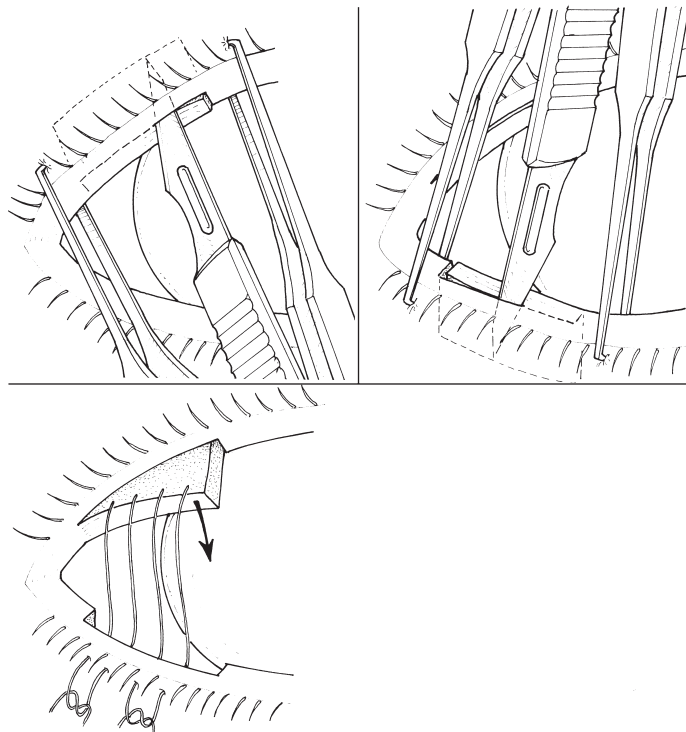


Figure 29.6. Tarsal transposition tarsorrhaphy. After splitting the lid margins and removing the margin epithelia, a back-cut helps create an upper lid tarsal tongue. A small amount of superior tarsus is removed from the lower lid to create the groove. The upper-lid tarsal tongue is sutured to the lower-lid tarsal groove employing either simple interrupted technique using 6-0 polyglactic acid sutures (Vicryl) or horizontal mattress technique using 4-0 chromic gut sutures. Partial thickness tarsal bites are employed to avoid ocular surface irritation. Comment: The depiction of the horizontal mattress sutures in the drawing is only meant to provide a general idea for the location of the sutures, and not a definitive illustration.

Reversal of a ‘permanent’ tarsorrhaphy can be performed in the office or the operating room. First, a local anesthetic is injected into both sides of the opposed lid margins, taking great care to avoid injury to the eye. A topical anesthetic drop is placed at the medial commissure and allowed to seep onto the ocular surface. A narrow malleable retractor can be placed over the ocular surface and under the opposed eyelid margins to provide protection to the ocular surface. A straight iris scissors or a #15 Bard-Parker blade is used to divide the tarsorrhaphy between the upper and lower lash lines. An ocular protective shield is then placed over the corneal surface, and minimal pinpoint cautery is used for hemostasis. No char should be left on the lid margin surface in order to avoid ocular irritation. Cautery-induced tissue contracture should be minimized. Gentle pressure for a few minutes with gauze over the closed eyelids will stop most bleeding. The possibility of lid margin abnormalities should be discussed prior to division of the tarsorrhaphy, and preferably even before the tarsorrhaphy procedure is performed.

SUMMARY

Corneal desiccation can be vision and eye threatening. Judicious use of lubrication and temporary or permanent lacrimal occlusion can be of great benefit to ocular surface health. Partial or complete closure of the lids with a temporary or permanent tarsorrhaphy can

provide a powerful protective measure, although these procedures will often interfere with vision. Overall, these are important tools in the armamentarium of the ophthalmologist.

REFERENCES

1. Lambiase A, Rama P, Aloe L, et al. Management of neurotrophic keratopathy. *Curr Opin Ophthalmol* 1999; 10: 270–276.
2. Murube J, Murube E. Treatment of dry eye by blocking the lacrimal canaliculi. *Surv Ophthalmol* 1996; 40: 463–480.
3. Freeman JM. The punctum plug: evaluation of a new treatment for the dry eye. *Trans Sect Ophthalmol Am Acad Ophthalmol Otolaryngol* 1975; 79: OP874–OP879.
4. Balam M, Schaumberg DA, Dana MR. Efficacy and tolerability outcomes after punctal occlusion with silicone plugs in dry eye syndrome. *Am J Ophthalmol* 2001; 131: 30–36.
5. Nava-Castaneda A, Tovilla-Canales JL, Rodriguez L, et al. Effects of lacrimal occlusion with collagen and silicone plugs on patients with conjunctivitis associated with dry eye. *Cornea* 2003; 22: 10–14.
6. Tai MC, Cosar CB, Cohen EJ, et al. The clinical efficacy of silicone punctal plug therapy. *Cornea* 2002; 21: 135–139.
7. Dohlman CH. Punctal occlusion in keratoconjunctivitis sicca. *Ophthalmology* 1978; 85: 1277–1281.
8. Kojima T, Dogru M, Ishida R, et al. Clinical evaluation of the Smart Plug in the treatment of dry eyes. *Am J Ophthalmol* 2006; 141: 386–388.
9. Altan-Yaycioglu R, Gencoglu EA, Akova YA, et al. Silicone versus collagen plugs for treating dry eye: results of a prospective randomized trial including lacrimal scintigraphy. *Am J Ophthalmol* 2005; 140: 88–93.
10. Willis RM, Folberg R, Krachmer JH, et al. The treatment of aqueous-deficient dry eye with removable punctal plugs. A clinical and impression-cytologic study. *Ophthalmology* 1987; 94: 514–518.
11. Kaido M, Goto E, Dogru M, et al. Punctal occlusion in the management of chronic Stevens-Johnson syndrome. *Ophthalmology* 2004; 111: 895–900.
12. Cohen EJ. Punctal occlusion. *Arch Ophthalmol* 1999; 117: 389–390.
13. White WL, Bartley GB, Hawes MJ, et al. Iatrogenic complications related to the use of Herrick lacrimal plugs. *Ophthalmology* 2001; 108: 1835–1837.
14. Mauriello JA, Esmali B, Ahmad A, et al. Management of complications after insertion of the SmartPlug punctal plug. *Ophthalmology* 2006; 113: 1859.e1–e6.
15. Maguire LJ, Bartley GB. Complications associated with the new smaller size freeman punctal plug. Case report. *Arch Ophthalmol* 1989; 107: 961–962.
16. Hsu HC. Ampullary pyogenic granuloma as a complication of lacrimal plug migration. *Chang Gung Med J* 2002; 25: 415–418.
17. Hurwitz JJ, Pavlin CJ, Rhemtulla el K. Identification of retained intracanalicular plugs with ultrasound biomicroscopy. *Can J Ophthalmol* 2004; 39: 533–537.
18. Rumelt S, Remulla H, Rubin PA. Silicone punctal plug migration resulting in dacryocystitis and canaliculitis. *Cornea* 1997; 16: 377–379.
19. Soparkar CN, Patrinely JR, Hunts J, et al. The perils of permanent punctal plugs. *Am J Ophthalmol* 1997; 123: 120–121.
20. Kim BM, Osmanovic SS, Edward DP. Pyogenic granulomas after silicone punctal plugs: a clinical and histopathologic study. *Am J Ophthalmol* 2005; 139: 678–684.
21. Fayet B, Assouline M, Hanush S, et al. Silicone punctal plug extrusion resulting from spontaneous dissection of canalicular mucosa: a clinical and histopathologic report. *Ophthalmology* 2001; 108: 405–409.
22. Rapoza PA, Ruddat MS. Pyogenic granuloma as a complication of silicone punctal plugs. *Am J Ophthalmol* 1992; 113: 454–455.

23. Akova YA, Demirhan B, Cakmakci S, et al. Pyogenic granuloma: a rare complication of silicone punctal plugs. *Ophthalmic Surg Lasers* 1999; 30: 584–585.
24. Linberg JV, Moore CA. Symptoms of canalicular obstruction. *Ophthalmology* 1988; 95: 1077–1079.
25. White WL, Glover AT, Buckner AB, et al. Relative canalicular tear flow as assessed by dacryoscintigraphy. *Ophthalmology* 1989; 96: 167–169.
26. Ogut MS, Bavbek T, Kazokoglu H. Assessment of tear drainage by fluorescein dye disappearance test after experimental canalicular obstruction. *Acta Ophthalmol (Copenh)* 1993; 71: 69–72.
27. Daubert J, Nik N, Chandeyssoun PA, et al. Tear flow analysis through the upper and lower systems. *Ophthal Plast Reconstr Surg* 1990; 6: 193–196.
28. Jones LT, Marquis MM, Vincent NJ. Lacrimal function. *Am J Ophthalmol* 1972; 73: 658–659.
29. Lemp MA, Weiler HH. How do tears exit? *Invest Ophthalmol Vis Sci* 1983; 24: 619–622.
30. Gerding H, Kupperts J, Busse H. Symptomatic cicatricial occlusion of canaliculi after insertion of Herrick lacrimal plugs. *Am J Ophthalmol* 2003; 136: 926–928.
31. Lee J, Flanagan JC. Complications associated with silicone intracanalicular plugs. *Ophthal Plast Reconstr Surg* 2001; 17: 465–469.
32. Herrick RS, Herrick R. Consider the cause when treating late-onset epiphora following occlusion therapy. *Ophthalmol Times* 2005; 30(10) May 15. Article obtained from <http://lacrimedics.com/articles.htm>.
33. Chou TY, Perry HD, Donnenfeld ED, et al. Pyogenic granuloma formation following placement of the Medennium SmartPLUG punctum plug. *Cornea* 2006; 25: 493–495.
34. Law RW, Li RT, Lam DS, et al. Efficacy of pressure topical anaesthesia in punctal occlusion by diathermy. *Br J Ophthalmol* 2005; 89: 1449–1452.
35. Obata H, Ibaraki N, Tsuru T. A technique for preventing spontaneous loss of lacrimal punctal plugs. *Am J Ophthalmol* 2006; 141: 567–569.
36. Vrabec MP, Elsing SH, Aitken PA. A prospective, randomized comparison of thermal cautery and argon laser for permanent punctal occlusion. *Am J Ophthalmol* 1993; 116: 469–471.
37. Benson DR, Hemmady PB, Snyder RW. Efficacy of laser punctal occlusion. *Ophthalmology* 1992; 99: 618–621.
38. Liu D, Sadhan Y. Surgical punctal occlusion: a prospective study. *Br J Ophthalmol* 2002; 86: 1031–1034.
39. Putterman AM. Canaliculectomy in the treatment of keratitis sicca. *Ophthalmic Surg* 1991; 22: 478–480.
40. Knapp ME, Frueh BR, Nelson CC, et al. A comparison of two methods of punctal occlusion. *Am J Ophthalmol* 1989; 108: 315–318.
41. Sahni J, Clark D. Argon laser and trichiasis: a helpful tip. *Br J Ophthalmol* 2001; 85: 762.
42. Wilcsek GA, Francis IC. Argon laser and trichiasis. *Br J Ophthalmol* 2003; 87: 375.
43. Cosar CB, Cohen EJ, Rapuano CJ, et al. Tarsorrhaphy: clinical experience from a cornea practice. *Cornea* 2001; 20: 787–791.
44. Seiff SR, Chang JS Jr. The staged management of ophthalmic complications of facial nerve palsy. *Ophthal Plast Reconstr Surg* 1993; 9: 241–249.
45. Megerian CA, McKenna MJ, Ojemann RG. Delayed facial paralysis after acoustic neuroma surgery: factors influencing recovery. *Am J Otol* 1996; 17: 630–633.
46. Chang L, Olver J. A useful augmented lateral tarsal strip tarsorrhaphy for paralytic ectropion. *Ophthalmology* 2006; 113: 84–91.
47. Courtright P, Lewallen S. Current concepts in the surgical management of lagophthalmos in leprosy. *Lepr Rev* 1995; 66: 220–223.
48. Sharma BR, Sharma M. Severe post thermal burn cicatricial ectropion with corneal ulceration: an illustrative case. *J Nepal Med Assoc* 2005; 44: 102–105.
49. Thompson KJ, Brand M. Temporary tarsorrhaphy: a valuable procedure in Hansen disease. *Arch Ophthalmol* 2003; 121: 149.
50. Tsubota K, Satake Y, Ohyama M, et al. Surgical reconstruction of the ocular surface in advanced ocular cicatricial pemphigoid and Stevens-Johnson syndrome. *Am J Ophthalmol* 1996; 122: 38–52.
51. Mondino BJ. Cicatricial pemphigoid and erythema multiforme. *Ophthalmology* 1990; 97: 939–952.
52. Johnson SM, Vestal RY. Lateral tarsorrhaphy for prevention of postoperative complications resulting from globe luxation. *J Cataract Refract Surg* 2003; 29: 1831–1833.
53. Rosenberg GJ. Temporary tarsorrhaphy suture to prevent or treat scleral show and ectropion secondary to laser resurfacing or laser blepharoplasty. *Plast Reconstr Surg* 2000; 106: 721–725; discussion 726–727.
54. Pushker N, Dada T, Vajpayee RB, et al. Neurotrophic keratopathy. *Clao J* 2001; 27: 100–107.
55. Clarke MP, Sullivan TJ, Kobayashi J, et al. Familial congenital corneal anaesthesia. *Aust N Z J Ophthalmol* 1992; 20: 207–210.
56. Lin PY, Cheng CY, Wu CC, et al. Bilateral neurotrophic keratopathy complicating Vidian neurectomy. *Am J Ophthalmol* 2001; 132: 106–108.
57. Franklin RM, Kenyon KR, Tutschka PJ, et al. Ocular manifestations of graft-vs-host disease. *Ophthalmology* 1983; 90: 4–13.
58. Portnoy SL, Inslar MS, Kaufman HE. Surgical management of corneal ulceration and perforation. *Surv Ophthalmol* 1989; 34: 47–58.
59. Bouchard CS. Lateral tarsorrhaphy for a noncompliant patient with floppy eyelid syndrome. *Am J Ophthalmol* 1992; 114: 367–369.
60. Quist LH. A simple and effective tarsorrhaphy technique without the use of external bolsters. *Ophthal Plast Reconstr Surg* 1993; 9: 148–149.
61. McInnes AW, Burroughs JR, Anderson RL, et al. Temporary suture tarsorrhaphy. *Am J Ophthalmol* 2006; 142: 344–346.
62. Donnenfeld ED, Perry HD, Nelson DB. Cyanoacrylate temporary tarsorrhaphy in the management of corneal epithelial defects. *Ophthalmic Surg* 1991; 22: 591–593.
63. Rouvelas H, Saffra N, Rosen M. Inadvertent tarsorrhaphy secondary to Dermabond. *Pediatr Emerg Care* 2000; 16: 346.
64. Ehrenhaus M, D'Arienzo P. Improved technique for temporary tarsorrhaphy with a new cyanoacrylate gel. *Arch Ophthalmol* 2003; 121: 1336–1337.
65. Voon LW, Chua CN, Hanson R. The use of N-butyl cyanoacrylate (indermil) in lateral tarsorrhaphy. *Arch Ophthalmol* 2004; 122: 279–281.
66. Diamond JP. Temporary tarsorrhaphy with cyanoacrylate adhesive for seventh-nerve palsy. *Lancet* 1990; 335: 1039.
67. Handschel JG, Depprich RA, Dirksen D, et al. A prospective comparison of octyl-2-cyanoacrylate and suture in standardized facial wounds. *Int J Oral Maxillofac Surg* 2006; 35: 318–323.
68. Puri P. Tissue glue aided lid repositioning in temporary management of involutional entropion. *Eur J Ophthalmol* 2001; 11: 211–214.
69. Rapoza PA, Harrison DA, Bussa JJ, et al. Temporary sutured tube-tarsorrhaphy: reversible eyelid closure technique. *Ophthalmic Surg* 1993; 24: 328–230.
70. Kitchens J, Kinder J, Oetting T. The drawstring temporary tarsorrhaphy technique. *Arch Ophthalmol* 2002; 120: 187–190.