

CLINICAL TECHNIQUES

Subcutaneous Forehead Lift: Technique and Early Results

Alon Kahana, MD, PhD; Bradley N. Lemke, MD; Cat N. Burkat, MD; Mark J. Lucarelli, MD

Objective: To present our indications, technique, and results for a modified subcutaneous forehead lift.

Methods: Retrospective chart review of 16 patients who underwent a subcutaneous forehead lift.

Results: Tumescant anesthesia was used in all 16 patients. Seven patients underwent the procedure without the use of a fibrin sealant, whereas a commercially available fibrin sealant was used in the other 9 surgeries. In 1 of 7 patients in whom a fibrin sealant was not used, a postoperative seroma was evacuated in the first 24 hours after surgery. In patients in whom a fibrin sealant was used, there were no cases of hematomas or seromas. Twelve patients had concomitant upper eyelid surgery (ptosis repair and/or blepharoplasty), and 4 patients had no upper eyelid surgery. Two patients had a small dehiscence with no long-term sequelae. There were no instances of keloid formation. Postoperative brow position was judged to be good in 9 patients, adequate in 4 patients, and undercorrected in 3 patients. Forehead rhytids were improved in all patients. There were 2 cases of asymmetry, 1 of them in a patient with a history of Bell's palsy. There were no cases of symptomatic postoperative scalp hypoesthesia or decreased forehead movement. Our analysis revealed a trend toward improved postoperative brow position with increasing experience, which was manifested in a more aggressive release of the subcutaneous attachments of the lateral brow and a larger skin excision.

Conclusions: Subcutaneous forehead lift with tumescant anesthesia and a fibrin sealant is a safe and effective technique that provides the surgeon with good control of brow positioning while directly addressing forehead rhytids.

It avoids significant postoperative scalp hypoesthesia. In our series, the use of a fibrin sealant was correlated with elimination of postoperative hematoma or seroma, even though these patients had no postoperative pressure dressings. This technique can be an important addition to the oculofacial surgical armamentarium.

Patients have many reasons for requesting forehead rejuvenation surgery: elevating ptotic brows to clear the visual axis (a functional brow lift), elevating ptotic brows to improve appearance, shortening a high forehead or raising a low forehead, and reducing forehead and glabellar rhytids are some common indications. The ideal forehead lift surgery will symmetrically reposition the brows to their normal anatomic location and reduce forehead rhytids while avoiding unsightly scars, scalp hypoesthesia, forehead paralysis, alopecia, contour abnormalities, or unwanted changes in forehead height. Many surgical techniques have been described, each with its own set of advantages and disadvantages.¹

The subcutaneous approach to the forehead lift has been described by Wolfe based on the unpublished technique of Tessier.^{2,3} However, a careful step-by-step description is lacking. The main advantages of this approach are the direct and powerful effects on rhytids, the excellent control of brow positioning, and the promise of minimal postoperative hypoesthesia. The main disadvantages are the long incisional scar and the vascular dissection plane.

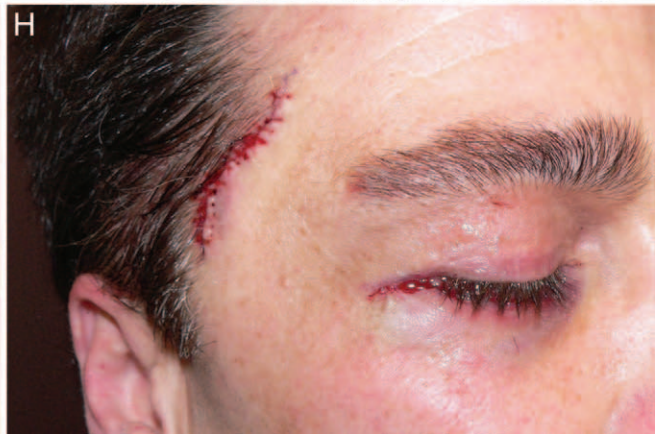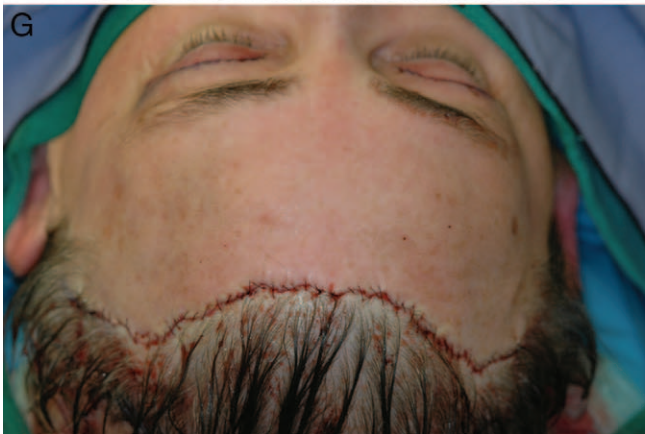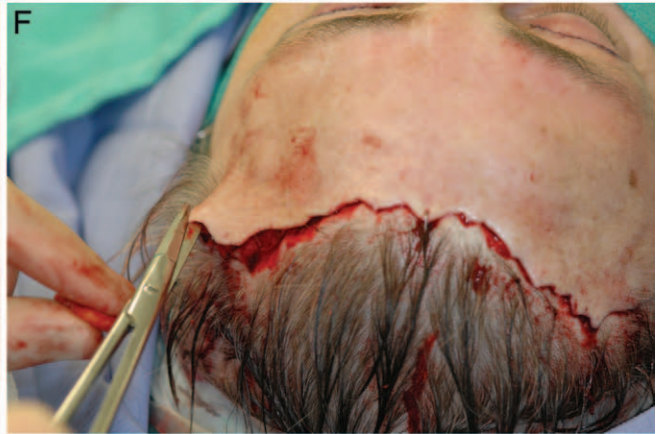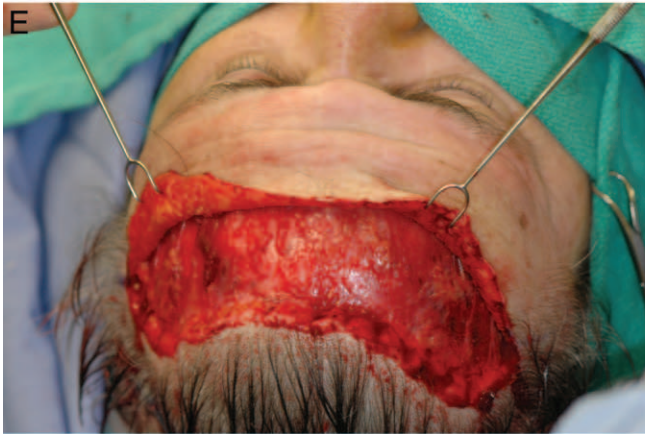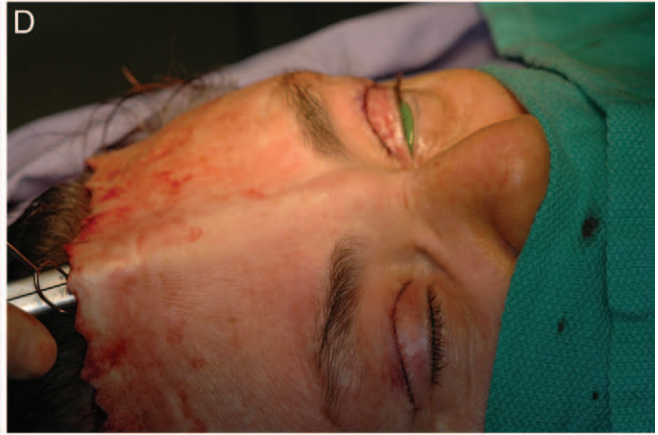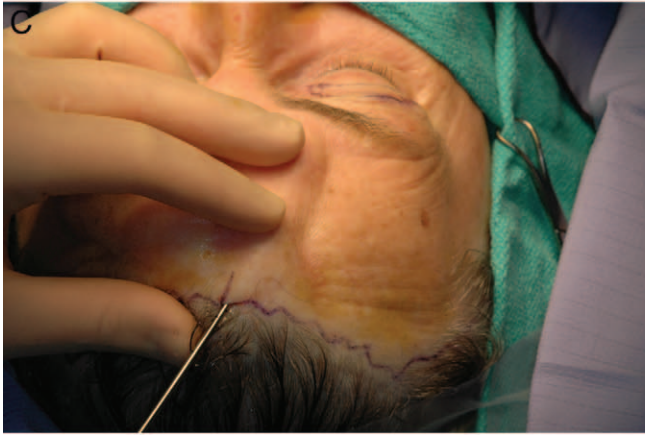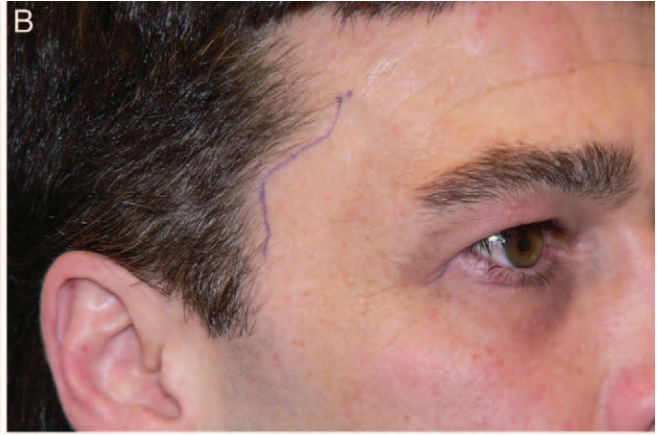
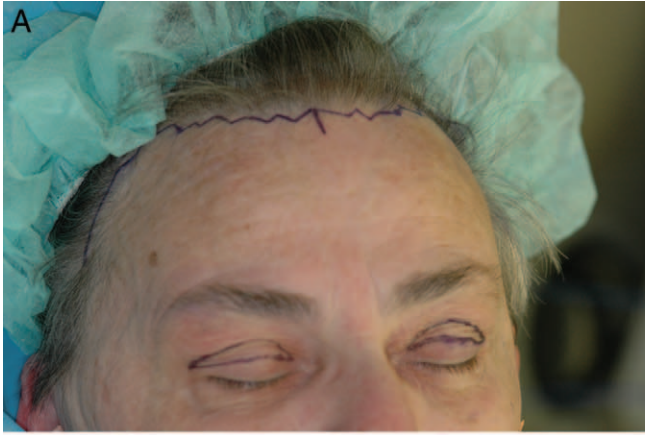This article describes our approach to the subcutaneous forehead lift, which we modified from a technique learned from Dr. Joseph Niamtu III (unpublished data, 200X). The technique uses an irregularly irregular pretrichial skin incision, tumescant anesthesia, a subcutaneous dissection plane, a commercial fibrin sealant (Tisseel, Baxter, Ill), and direct rhytidectomy with skin excision. We believe this technique can be a good

Received for publication Month, day, year.

From the Oculoplastics Service, Department of Ophthalmology and Visual Sciences, University of Wisconsin, Madison (Dr Kahana, Dr Burkat, Dr Lucarelli) and Lemke Facial Surgery, Madison, WI (Dr Lemke).

Dr Kahana is currently with Eye Plastic, Orbital and Facial Cosmetic Surgery, Department of Ophthalmology and Visual Sciences, Kellogg Eye Center, University of Michigan, Ann Arbor.

Corresponding Author: Alon Kahana, MD, PhD, University of Michigan, Ophthalmology and Visual Sciences, Kellogg Eye Center, 1000 Wall St, Ann Arbor, MI 48105 (e-mail: akahana@med.umich.edu).



addition to the armamentarium of the oculofacial plastic surgeon.

Methods

Surgeries were performed by each of the authors, and the charts and photographs were reviewed by the primary author (A.K.). This retrospective study was reviewed and approved by the Institutional Review Board of the University of Wisconsin. Assessment of brow position was made by the primary author based on chart notes and clinical photographs, including the position of the brow relative to the pupillary reflex or the inferior limbus. In some cases, the photographer did not use a standardized template for pre- and post-operative photos. In these cases, assessment utilized a “gestalt” approach along with the clinic notes.

Sixteen patients had undergone a subcutaneous forehead lift, and their charts were reviewed. Indications included both cosmetic and functional complaints. Seven patients had the surgery performed without the use of a fibrin sealant. All the other patients had the surgery performed with the use of a fibrin-based tissue sealant.

Surgical Technique

The recommendation of a subcutaneous forehead lift was made when forehead and brow ptosis were deemed too severe to address with an internal brow lift or an endoscopic forehead lift, and the patient wished to avoid scalp hypoesthesia or a supraciliary or mid-forehead scar. The indications included severe forehead rhytids in cosmetic cases and severe brow ptosis in functional cases.

The procedure begins with marking a pretrichial incision at the very edge of the hairline. The pretrichial incision was constructed with irregularities to camouflage the scar (Figure 1A).⁴ For patients whose brow ptosis was most problematic laterally, isolated bitemporal pretrichial incisions were marked (Figure 1B).

Next, the incision line was infiltrated with local anesthetic containing 1% lidocaine, 0.25% bupivacaine, and 1:100,000 dilution of epinephrine. The patient’s face was then cleaned with Betadine solution

and draped in a sterile fashion. The Betadine preparation extended 2–3 inches into the hairline.

A small, central, beveled stab incision was made with a scalpel and used for infiltrating tumescent anesthetic solution through a blunt cannula, using 0.1–0.2% lidocaine and 1:500,000–1:1,000,000 dilution of epinephrine in 0.9 normal saline (a modification of Klein’s tumescent solution).⁵ Care was taken to place the tumescent solution in a subcutaneous plane, between frontalis muscle and dermis, achieving hydrodissection of the subcutaneous surgical plane (Figure 1C). Using a blunt cannula helps prevent penetration of the frontalis muscle with submuscular injection of tumescent solution. It also helps prevent intravascular injection. The tumescent solution was allowed to take effect for at least 10 minutes. If eyelid surgery was planned, it was performed at this point, with particular attention to ensuring that sufficient eyelid skin would be retained.

Next, a beveled incision was made along the previously placed pretrichial marks. A mostly blunt subcutaneous dissection was performed, taking advantage of the subcutaneous hydrodissection achieved with the tumescent solution (Figure 1D). The dissection extended into the glabellar region to separate the dermis from the procerus and corrugator muscle insertions. The lateral subcutaneous dissection was extended until the desired lift could be achieved. Good hemostasis was achieved with the tumescent anesthesia as well as pinpoint cautery (Figure 1E). Direct myectomy could be performed at this point through a blepharoplasty incision, but it was not done in this series.

Achieving the desired mild overcorrection usually required a subcutaneous dissection that extended under the tail of the brow, undermining the cutaneous insertions of the connective tissue attachments. As the subcutaneous dissection is performed, forehead elevation is tested to assess progress. Once the appropriate amount of dissection was performed, the forehead was mobilized to raise the brows to the desired level, and the brow contour was addressed by adjusting the vectors of mobilization. The appropriate strip of forehead skin was excised to fit with the irregularly irregular incision structure as well as the incisional beveling (Figure 1F).

Figure 1. Technique. (A) Pretrichial markings. (B) Bitemporal markings. (C) Tumescent anesthesia injection with a blunt cannula. (D) Blunt subcutaneous dissection extending into the glabellar region. (E) The subcutaneous dissection leaves the frontalis muscle undisturbed; tumescent anesthesia, along with judicious use of pinpoint cautery, is helpful in achieving hemostasis. (F) Excess skin is trimmed to achieve the desired lift. The trimming is beveled, and corresponds to the irregular incision line. (G) Closure of the pretrichial incision. (H) Closure of the limited temporal incision.

Patient List

Patient	Age	Indication	Eyelid Surgery	Extent of Lift	Scalp Hypoesthesia	Fibrin Sealant	Complications	Brow Position
1	73	Cosmetic	Blepharoplasty	Full	No	No	Small dehiscence	Good
2	53	Paralytic	Blepharoplasty	Full	No	No	Mild asymmetry	Adequate
3	62	Cosmetic	No	Full	No	No	Postoperative seroma	Undercorrected
4	57	Cosmetic	Blepharoplasty	Full	No	No	None	Adequate
5	55	Cosmetic	No	Full	No	No	None	Good
6	53	Cosmetic	Levator repair/blepharoplasty	Full	No	No	None	Undercorrected
7	54	Cosmetic	Levator repair/blepharoplasty	Full	No	Yes	None	Good
8	86	Functional	Blepharoplasty	Full	No	Yes	None	Undercorrected
9	51	Cosmetic	Blepharoplasty	Full	No	Yes	Small dehiscence	Good
10	67	Functional	Levator repair/blepharoplasty/ectropion repair	Temporal lift	No	Yes	None	Good
11	56	Cosmetic	No	Full	No	Yes	None	Adequate
12	43	Cosmetic	No	Temporal lift	No	No	None	Good
13	78	Functional	Blepharoplasty	Full	No	Yes	None	Good
14	65	Functional	Blepharoplasty	Full	No	Yes	None	Good
15	74	Functional	Blepharoplasty	Full	No	Yes	Mild asymmetry	Adequate
16	57	Functional	Blepharoplasty	Full	No	Yes	None	Good

Temporarily placed central and paracentral staples were very helpful with this maneuver.

At this point, attention was directed to achieving meticulous hemostasis using pinpoint cautery with a monopolar cautery unit and a microdissection tip or an Ellman radiofrequency knife and a needle or ballpoint tip (Ellman Instruments, Oceanside, NY). Subcutaneous incision closure was achieved with buried interrupted 5-0 polyglactin (Vicryl) or poligle-caprone (Monocryl) sutures. When fibrin sealant was used, it was injected into the dissection plane between the subcutaneous sutures, making sure to cover the entire dissection plane. A forehead typically required 2 mL of fibrin sealant (Tisseel, Baxter, Ill).

Direct pressure to the forehead was applied for approximately 3 minutes to achieve good adhesion and closure of the subcutaneous dissection plane. Next, 5-0 nylon or plain gut suture was used to close the pretrichial incision, while staples were used to close the incision laterally through hair-bearing skin (Figure 1G). Bitemporal incisions were closed in a similar fashion (Figure 1H). Nylon sutures and/or staples were removed 7–9 days after surgery. Patients in whom a fibrin sealant was not used were bandaged with ABD pads, a conforming stretch bandage such as Kerlix dressing,

an adherent wrap (Coban, 3M, Minn), and sometimes an elastic tubular net bandage.

Results

Fourteen patients underwent a full subcutaneous forehead lift, and two patients had a limited bitemporal subcutaneous lift (Table). Preoperative indications included functional complaints, which were severe and included visually significant involuntarily or paralytic brow ptosis. Cosmetic symptoms included excessive forehead rhytids, brow ptosis that was not visually significant, significant brow asymmetry, and contour concerns. Patient follow-up ranged from 2 months to 1 year.

Nine patients underwent a cosmetic forehead lift. Average patient age was 56 years. Six patients had concomitant eyelid surgery (Figure 2), and the other 4 underwent an isolated forehead lift (Figure 3). In 3 of 9 cosmetic patients, a fibrin sealant was used. Complications included a moderate postoperative seroma in one of the patients for whom a fibrin sealant was not used. This was evacuated with a large-bore needle. Two patients experienced a mild wound dehiscence 2–3 weeks after surgery. The dehiscences measured less than 15 mm in length and represented 2–3 mm of tissue

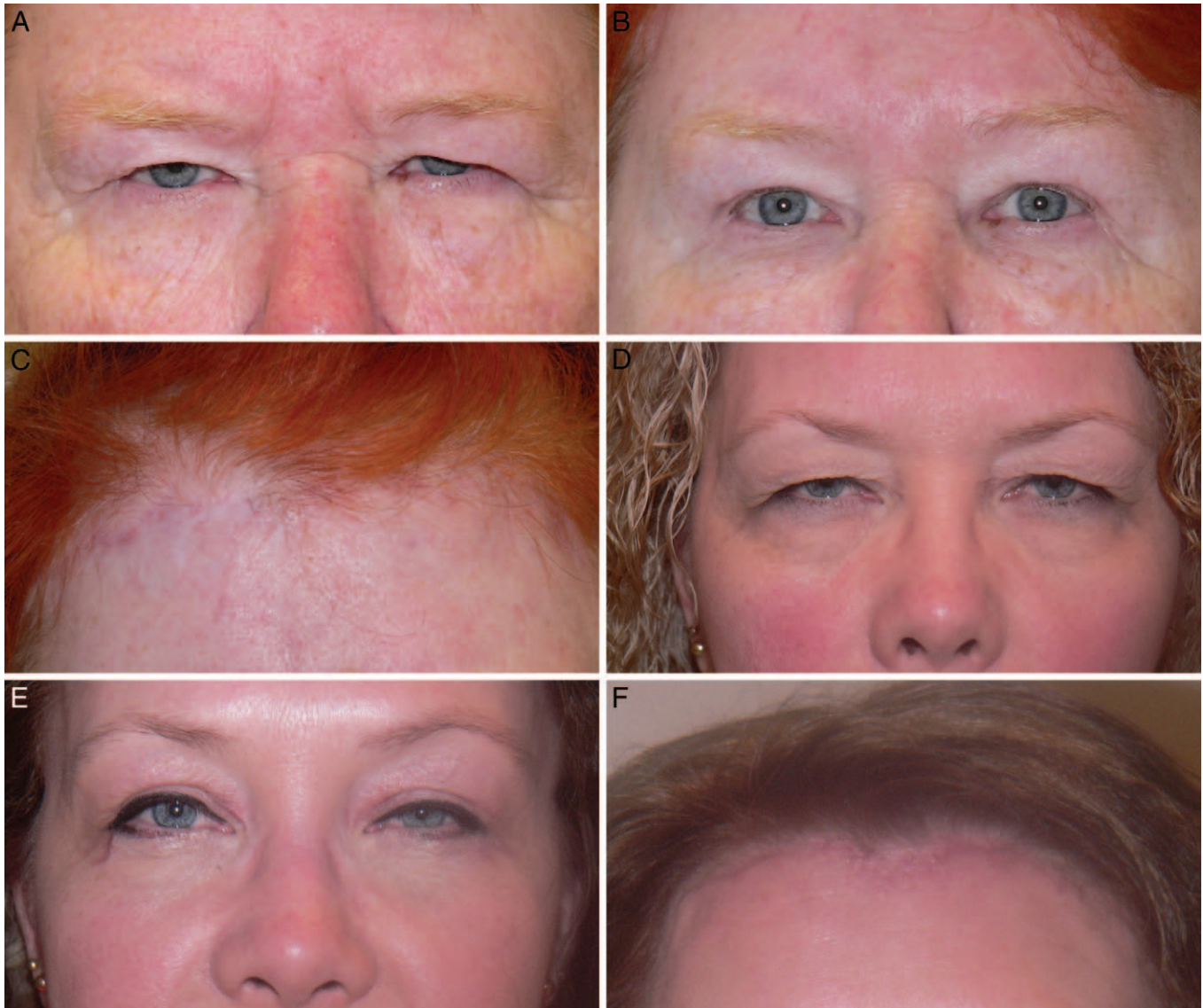

Figure 2. *Cosmetic surgery involving forehead and upper lids. (A and B) Before surgery and 4 months after surgery. (C) Incisional scar at 4 months. (D and E) Before surgery and 2 months after surgery. (F) Incisional scar at 2 months. In both cases, upper lid blepharoplasties were performed.*

separation. The dehiscences were allowed to heal secondarily, and the resultant scars were mild enough that the patients declined complimentary scar revision. After photographic review, 2 patients were judged to have been undercorrected (Table). Nevertheless, patient satisfaction was high.

Seven patients underwent a functional forehead lift (Figure 4). Average patient age was 68.6 years. Tisseel fibrin sealant was used for 6 of these 7 patients, and all functional patients had concomitant eyelid surgery. There were no instances of seromas, and a pressure dressing was used in only one of the patients in whom a fibrin sealant was used because this patient was on

warfarin, which was stopped before surgery but was to be resumed the night after surgery. This same patient was also the only one with notable bruising despite the use of fibrin sealant. The bruising resolved within 3 weeks. She also developed mild asymmetry. Nevertheless, she was very satisfied with her functional result. One functional patient with paralytic brow ptosis had residual asymmetry that was functionally insignificant, and the patient was very happy with the result. One patient was judged by photographic review to have been undercorrected (Table). However, on questioning, patient satisfaction was uniformly high.

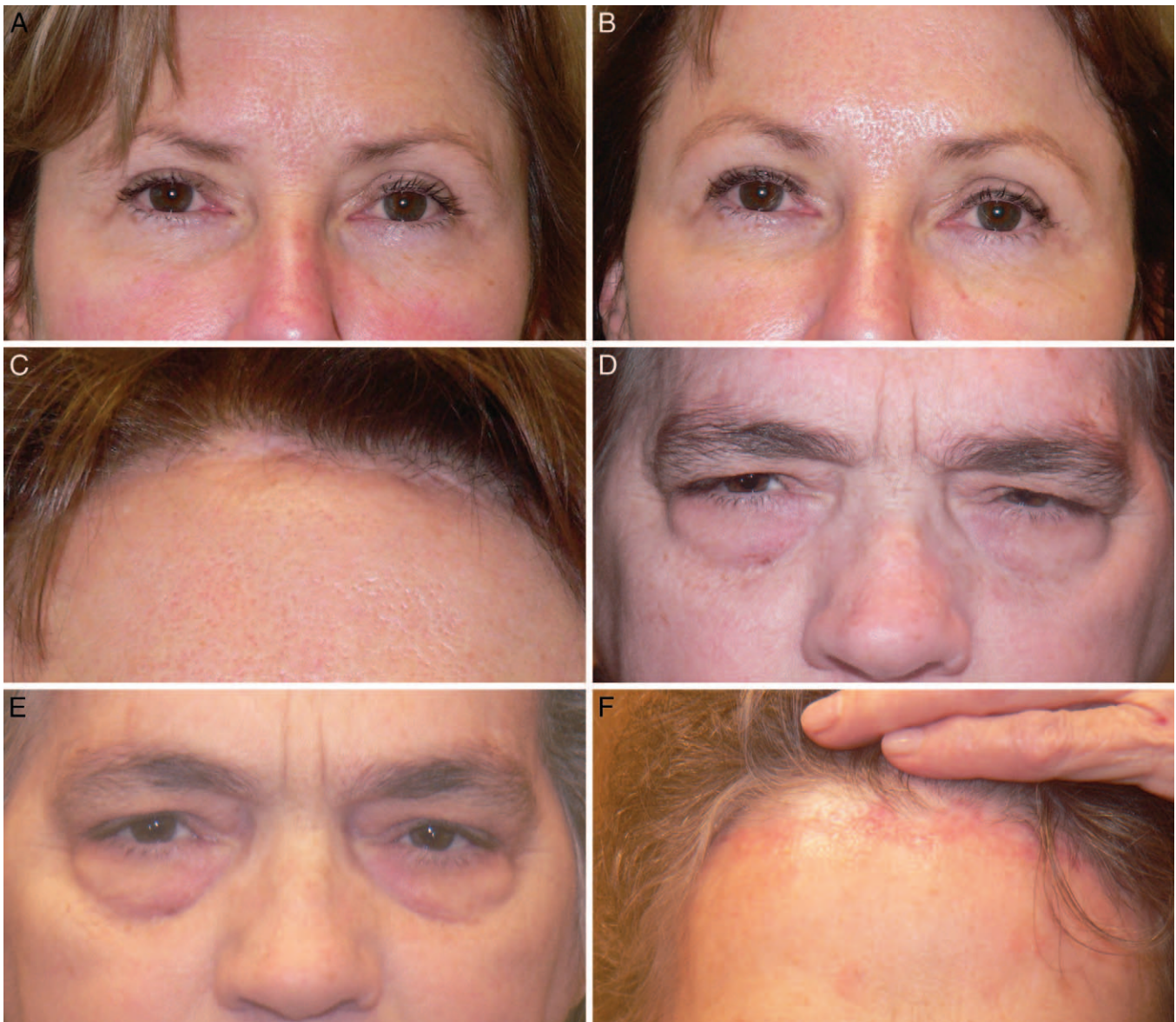

Figure 3. Isolated cosmetic forehead lift. (A and B) Before surgery and 2 months after surgery. (C) Incisional scar at 2 months. (D and E) Before surgery and 3 months after surgery. (F) Incisional scar at 3 months. In both cases, no eyelid surgery was performed.

In both groups, there were no instances of symptomatic scalp hypoesthesia that lasted longer than a few days. When postoperative hypoesthesia occurred, it was minimal and limited to the incisional area and the area immediately posterior to it.

Discussion

The surgical techniques for a forehead lift are varied, reflecting the different goals and expectations of patients and surgeons. These techniques differ in the location of the incision and the plane of dissection. The traditional bicoronal forehead lift uses a scalp

incision and a subgaleal and/or subperiosteal dissection plane. The pretrichial technique is an anterior variant of the bicoronal flap that helps with patients who have higher foreheads. These techniques use the relatively avascular subgaleal and subperiosteal dissection planes, and they can achieve excellent brow repositioning and some elimination of rhytids. Their major downside is long-lasting scalp hypoesthesia, which is worse when using the pretrichial incision. With more posterior incisions, the hypoesthesia is lessened but the effectiveness of the rhytidectomy is reduced as well.

As a result of the limitations of the pretrichial and bicoronal lift techniques, many surgeons (including the authors of this report) use an endoscopic forehead lift via several small incisions behind the hairline.^{6,7} The main dissection plane is still the relatively avascular subperiosteal plane. The endoscopic forehead lift requires greater surgical expertise, along with specialized and expensive equipment.⁸ This technique can provide adequate and long-lasting brow elevation, but it has a more limited effect on static forehead rhytids. Variations that are not dependent on endoscopy have also been described.⁹

Combining the pretrichial and endoscopic techniques has been advocated and described.¹⁰ This technical variant uses the endoscopic approach for the forehead and brow elevation and adds a limited pretrichial subcutaneous approach for direct rhytidectomy. Another approach uses a subperiosteal temporal forehead lift combined with a trans-blepharoplasty myectomy of the corrugator, depressor, and procerus muscles.¹¹ This approach directly addresses lateral brow position, and indirectly addresses medial brow position. Because of the corrugator myectomy, glabellar widening can be noted after surgery. This technique addresses dynamic glabellar rhytids but not static rhytids, and the long-term efficacy has been questioned by some surgeons given that the myectomized muscles may heal and reinsert.⁸

In this article we describe our use of the subcutaneous forehead lift in both functional and cosmetic patients. The biggest change in our technique over time was the introduction of tumescent anesthesia and fibrin sealant. Tisseel is one of several commercially available fibrin sealants. It is the authors' impression that the fibrin sealant significantly helped to reduce bruising and edema with this procedure. Although we initially gave our cosmetic patients the option of using a fibrin sealant, we now view it as an integral part of our surgical technique. Additional alterations in technique over time included: (1) more aggressive undermining of the lateral brow subcutaneous attachments for greater mobilization of the brow, with extension of the subcutaneous dissection to the zygomaticofrontal suture and release of the temporal fusion line; and (2) intraoperative overcorrecting of the brow in the supine position, which leads to improved long-term postoperative brow position.⁸

In our series, patient satisfaction was excellent. Both cosmetic and functional patients often commented on the improvement in forehead rhytids. Before surgery, patients were always informed about the potential for significant scarring and alopecia. However, the scarring has proved to be minimal by 6 months after the

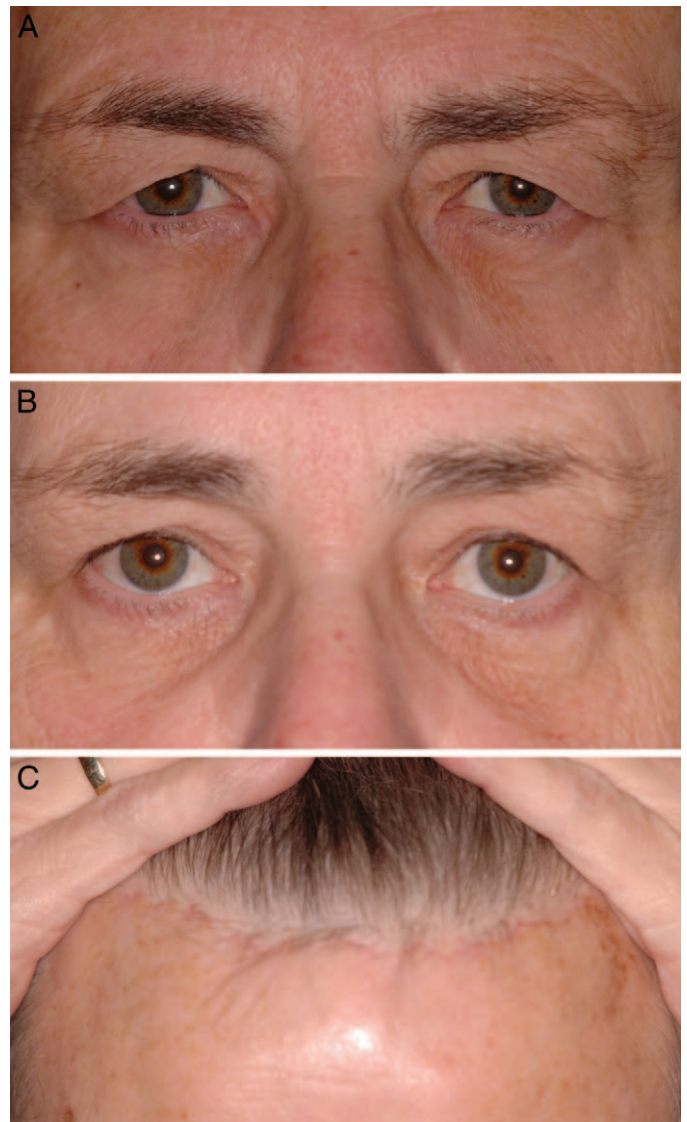


Figure 4. Combined functional forehead lift and upper lid blepharoplasties. (A and B) Before surgery and 3 months after surgery. (C) Incisional scar at 2 months.

procedure, and patients have been very pleased with the appearance of their wounds and their foreheads. In 2 instances in which the scar was more apparent (after a small dehiscence; Figure 2C), the patients could easily hide their scar behind hair bangs while the scar continued to remodel over time.

Relative contraindications to the subcutaneous forehead lift included heavy smoking, diabetes with systemic complications, and other conditions that can compromise wound healing and/or the immune response.

The initial impetus for using the subcutaneous forehead lift was to reduce postoperative scalp hypoesthesia while still providing a strong and long-lasting lift for patients with severe forehead ptosis and rhytids.

By staying in a subcutaneous plane, the deep branches of the supraorbital and supratrochlear nerves that supply the scalp are left undisturbed. With the introduction of the subcutaneous forehead lift technique into our practice, patients have noted only incisional hypoesthesia that generally subsided over a few weeks. The risk of facial nerve injury exists in all forehead lifting techniques, and with this technique the risk is minimized by staying in a subcutaneous plane above the frontalis and temporalis muscles. In our small series, no patient experienced an injury to the temporal branch of the facial nerve.

Overall, this modified subcutaneous forehead lift technique proved to be safe and useful for both functional and cosmetic purposes. Its advantages of a direct rhytidectomy, powerful brow positioning ability, safety profile, and the opportunities to tailor the surgery to the needs of each patient have made the subcutaneous forehead lift technique an attractive option for a challenging subset of patients with more severe brow ptosis.

Acknowledgment

Supported in part by an unrestricted grant from Research To Prevent Blindness (New York, NY) to the Department of Ophthalmology and Visual Sciences, University of Wisconsin, Madison.

References

1. Paul MD. The evolution of the brow lift in aesthetic plastic surgery. *Plast Reconstr Surg.* 2001;108:1409–1424.
2. Wolfe SA. The subcutaneous forehead lift, revisited. *Plast Reconstr Surg.* 2000;105:449–450.
3. Wolfe SA, Baird WL. The subcutaneous forehead lift. *Plast Reconstr Surg.* 1989;83:251–256.
4. de Benito J. Aesthetic incision in the subcutaneous forehead lift. *Aesthetic Plast Surg.* 1993;17:239–242.
5. Klein JA. Anesthesia for liposuction in dermatologic surgery. *J Dermatol Surg Oncol.* 1988;14:1124–1132.
6. Ramirez OM, Robertson KM. Update in endoscopic forehead rejuvenation. *Facial Plast Surg Clin North Am.* 2002;10:37–51.
7. Namazie AR, Keller GS. Current practices in endoscopic brow and temporal lifting. *Facial Plast Surg Clin North Am.* 2001;9:439–451.
8. Niamtu J III. Endoscopic brow and forehead lift: a case for new technology. *J Oral Maxillofac Surg.* 2006;64:1129–1132.
9. Kikkawa DO, Miller SR, Batra MK, Lee AC. Small incision nonendoscopic browlift. *Ophthalm Plast Reconstr Surg.* 2000;16:28–33.
10. Tower RN, Dailey RA. Endoscopic pretrichial brow lift: surgical indications, technique and outcomes. *Ophthalm Plast Reconstr Surg.* 2004;20:268–273.
11. Knize DM. Limited-incision forehead lift for eyebrow elevation to enhance upper blepharoplasty. *Plast Reconstr Surg.* 1996;97:1334–1342.